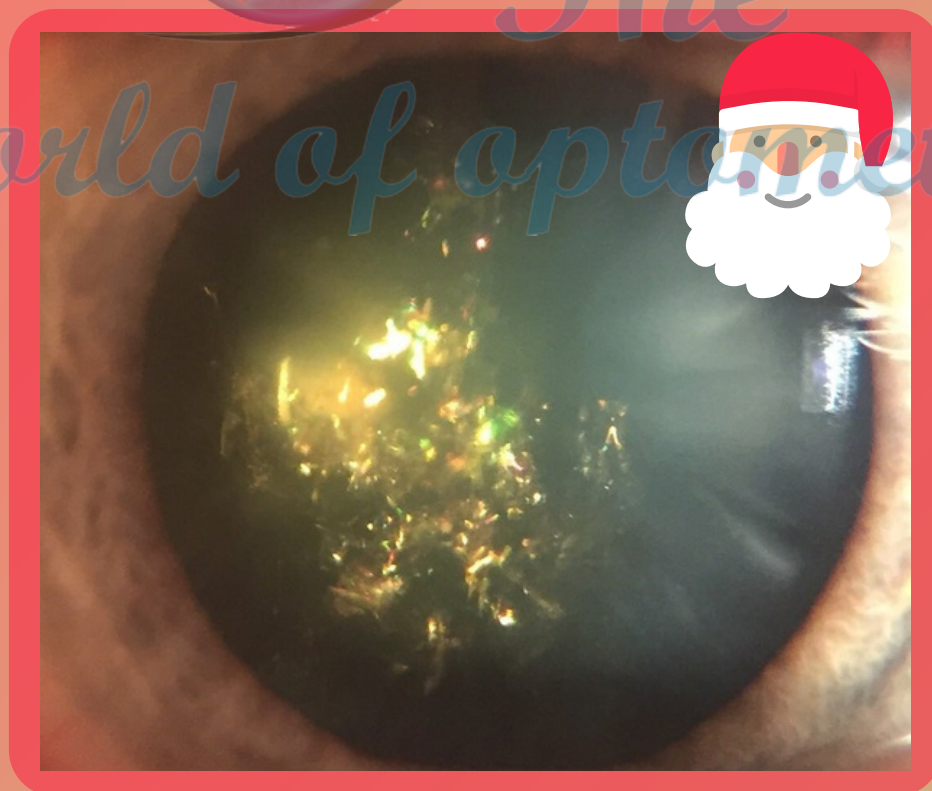


TWOP Discussion


CHRISTMAS TREE CATARACT



#TwopDiscussion

INTRODUCTION

- Christmas tree cataract, is a rare age-related condition, in which changes occurs in the crystalline lens.
- Resulting from accelerated breakdown of membrane-associated denatured proteins induced by **elevated calcium levels**, characterized by polychromatic needle-shaped deposits in the **deep cortex and nucleus** which may be associated to other opacities.
- It is presented unilaterally or asymmetrically bilaterally.



#TwopDiscussion

ETIOLOGY

- There are various theories about the **composition of the deposits.**
- Some studies indicate they are cholesterol crystals caused by the **change** in cell metabolism, others believe they are formed from cystine which is released when crystalline break down,
- While some believe that it is just an anomaly in the **diffraction of light** as it reflects off **cells** that have fused in the crystalline lens.



Clear Lens



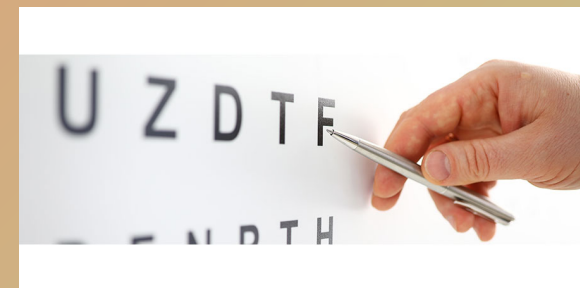
Lens colored by Cataract



The World of Optometry

CLINICAL FEATURES & SYMPTOMS

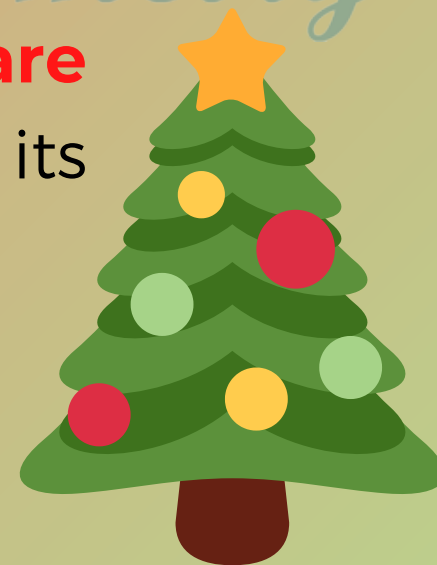
- Typically there are **no** associated pathologies with Christmas tree cataracts
- Most patients who have it are fit and well.
- In either case the opacities offers no **threat to visual acuity.**
- They may develop a little over time, but **surgery is avoided** where possible as the reflective properties of the opacity impair the view of the surgeon while performing the procedure.



#TwopDiscussion

DISCUSSION


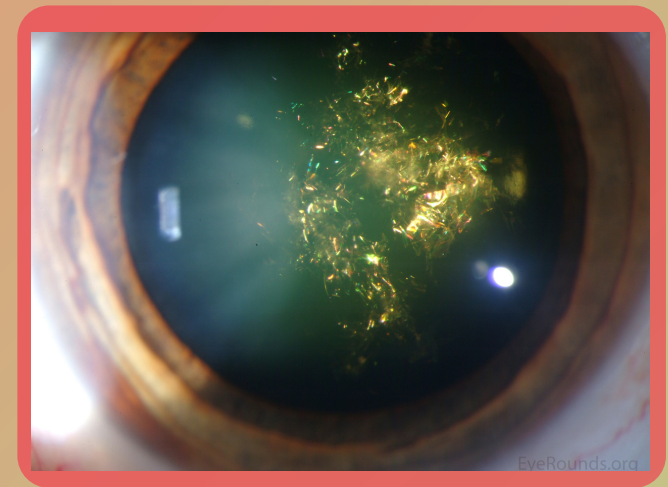
- This type of change has already been the subject of several clinical discussions, and the composition of said opacities is still controversial.
- The **colors** vary according to the angle of incident light and the colors **red and green are predominant**, which explains its nomenclature.



#TwopDiscussion

DISCUSSION

- Since the brightness and variety of colors refers to the ornaments that commonly decorate the **Christmas tree**.
- It is frequently observed in people who suffers from Steinert's disease which is a type of myotonic dystrophy.




#TwopDiscussion



Wow, what cool content



Leave your comment



Share with friends



Save, to consult in the future

The World of optometry



The World of Optometry



@theworldofoptometry



TheWorldofOptometry



TheWorldofOptometry