



*The World
of Optometry*

Two Case Study

**Convergence Excess With
Normal Tonic Vergence**



@theworldofoptometry




TheWorldofOptometry



TheWorldofOptometry

#TwoCaseStudy

Patient History




CHIEF COMPLAINTS: A 18 years old boy presented with complaint of inability to read comfortably for more than 10 mins. He also complained of pulling sensation, headache and sleepiness while studying.

OCULAR HISTORY: None.

PAST MEDICAL HISTORY: His medical history was negative and was not taking any medications. This was his second eye examination and health status was normal. Earlier doctor had prescribed him glasses around a year ago but it did not solve those problems.

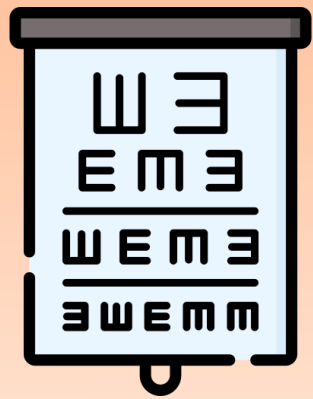
FAMILY HISTORY: None.



Clinical Examination

Distance Visual acuity(DVA) (uncorrected)

- 20/20 OU



Near Visual acuity(NVA) (uncorrected)

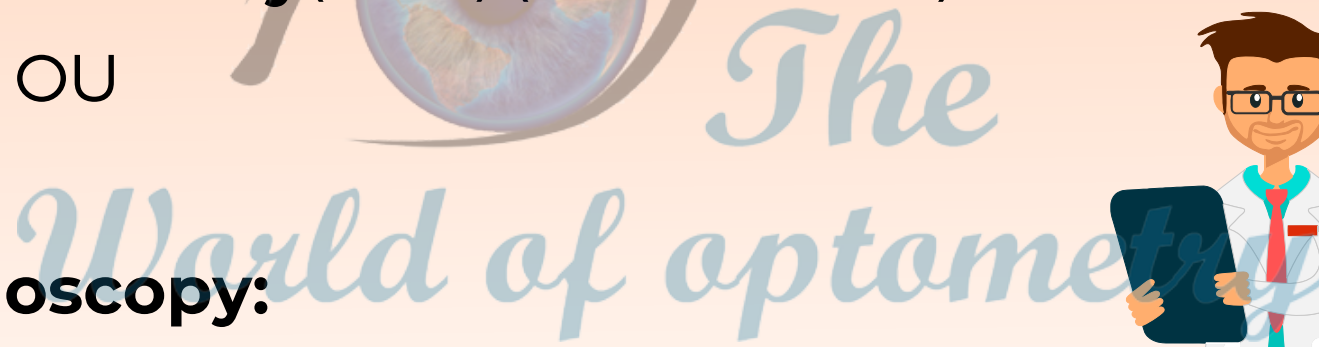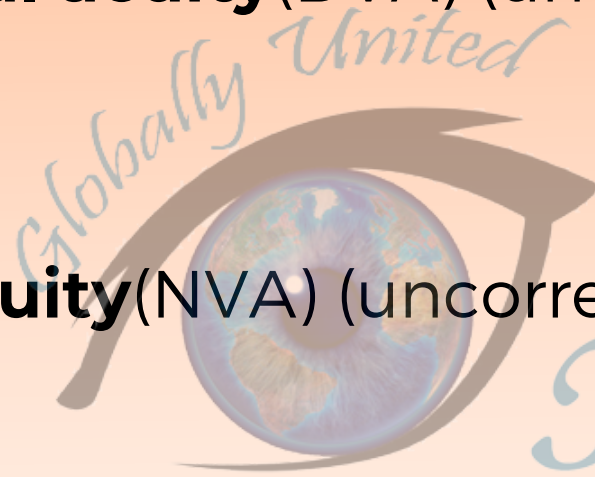- 20/20 OU

Net Retinoscopy:

- Plano BE

Refractive Acceptance:

- -Plano BE



The World of Optometry

#TwopCaseStudy

Orthoptic Evaluation

EOM: Full, Free, Painless all 9 gaze



NPC: 5cm

Cover Test (Distance): Orthophoria

Cover Test (Near): 15 Esophoria at near

NRA: +2.50

PRA: Diplopia at Plano



The World of Optometry



@theworldofoptometry



TheWorldofOptometry



TheWorldofOptometry

#TwopCaseStudy

Orthoptic Evaluation


MAF: 10 CPM OD/ 12 CPM OS

BAF: Diplopia with -2.00D

VF: 0 CPM Diplopia With BI

Calculated AC/A ratio: 12:5:1


MEM Retino: +1.50D




DRAG TO THE SIDE
DRAG TO THE SIDE

#TwopCaseStudy

Diagnosis



Convergence Excess With
Normal Tonic Vergence



@theworldofoptometry



TheWorldofOptometry




TheWorldofOptometry

Management Plan

- Added Lenses for near work based on clinical findings
- Brock string exercise 5-6 minutes Bd
- Lens sorting
- Loose Lens Rock(with Plus)
- Aperture Rule
- Carboxy Methyl Cellulose E/d Qid



Globalby United
The World of Optometry




Management Plan

Post follow up after 9 weeks:

- **NPC:** 5cm
- **Cover test:** BE Orthophoria @ distance
- **Cover test :** BE Orthophoria @ near
- **VF:** 9cpm
- **NRA:** +2.50D
- **PRA:** -1.25D



Patient was happy and satisfied after follow up visit to hospital as the symptoms got relieved.

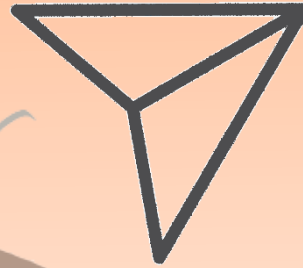





Wow, what a cool content



Leave your comments




Share with friends



Save, to consult in the future

The World of optometry



@theworldofoptometry



TheWorldofOptometry



TheWorldofOptometry