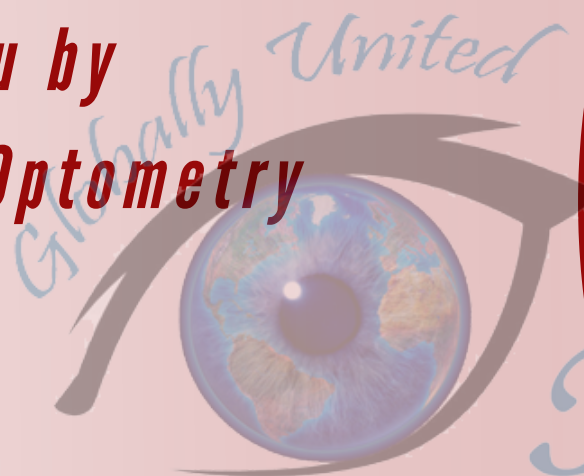

“

# TWOP TIPS

*brought to you by  
The World of Optometry*



# HOW TO TACKLE A PATIENT BASED ON COMPLAINS PART 3



#TwopTips



@theworldofoptometry



TheWorldofOptometry



TheWorldofOptometry

## TIPS

### 1. HEADACHE


- SUDDEN ONSET : anterior + posterior segment (Optic Neuritis, AACG, scleritis, uveitis, papilledema).

**Test to perform:** VA, Refraction (if necessary), Pupil reflex, OCT, Funduscopy.



- PROGRESSIVE : anterior segment + posterior segment (Refractive errors, Keratoconus, Binocular vision Anomalies, Glaucoma)

**Test to perform:** VA, Refraction, Topography and Orthoptic Assessment.



## TIPS

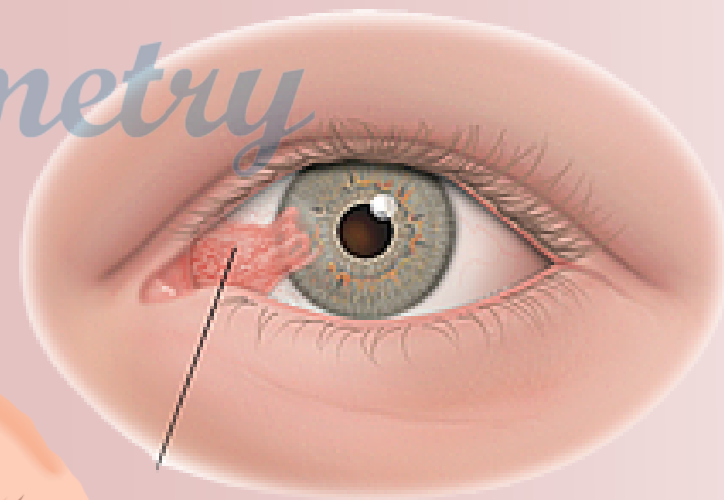
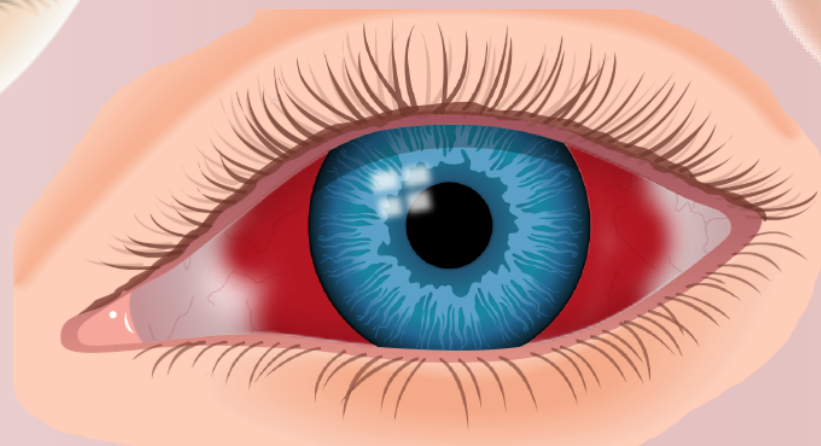
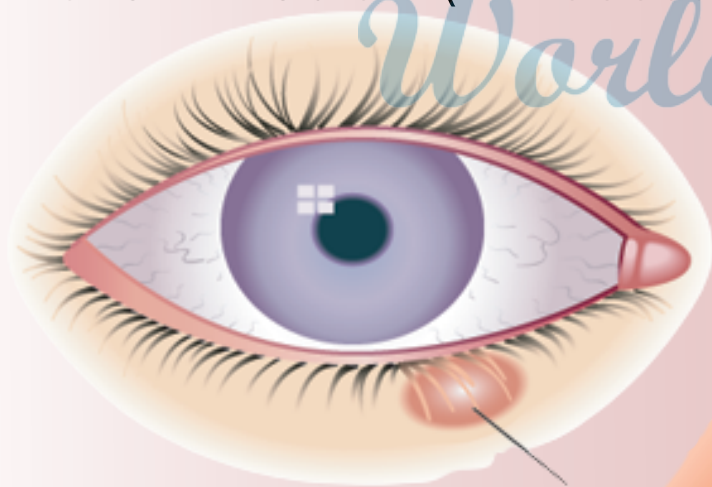### 2. RED EYE

- LIDS: Blepharitis, Marginal Keratitis, Trichiasis, Chalazion, Stye, Foreign Body.

**Test to perform:** VA, Slit Lamp Examination.

- CONJUNCTIVA: Bacterial conjunctivitis, Viral conjunctivitis, Allergic conjunctivitis, Subconjunctival hemorrhage, Pterygium.

**Test to perform:** VA, Slit lamp examination & Dilated fundus examination (if necessary).





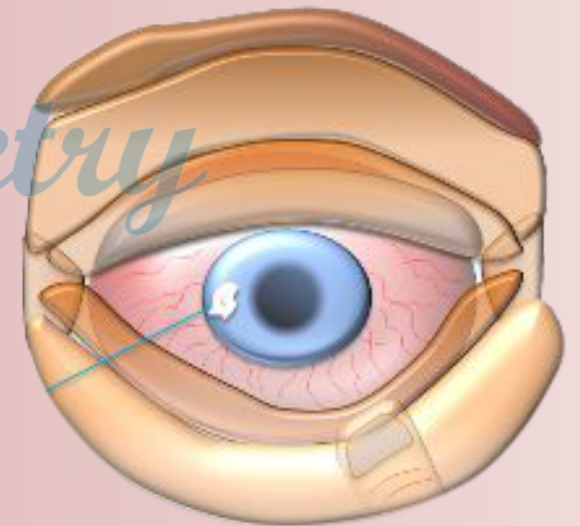
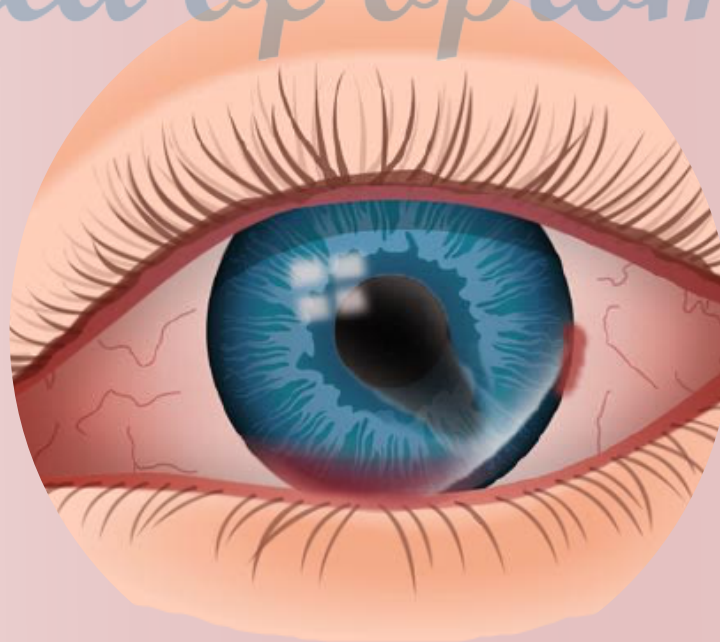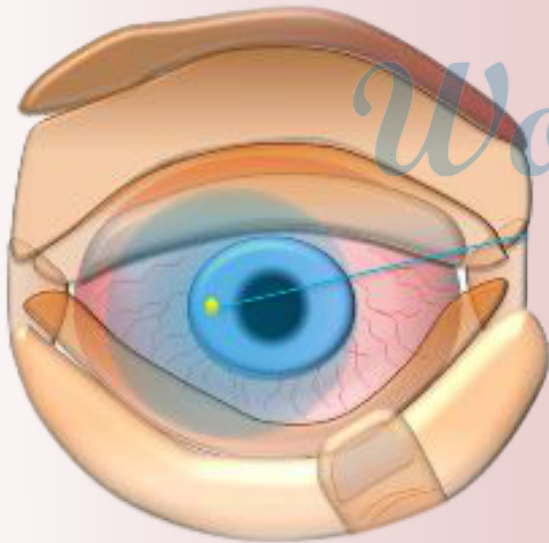
## TIPS

- CORNEA : Bacterial keratitis, Herpetic keratitis, Foreign body, Episcleritis, Scleritis, Corneal ulcer, Corneal abrasion, Dry eyes.

**Test to perform:** VA, Slit lamp examination,

- ANTERIOR CHAMBER : Anterior uveitis, Acute angle closure glaucoma, Trauma.

**Test to perform:** VA, Refraction, Pupil reflex, Slit lamp examination, OCT, Funduscopy.



## TIPS

### 3. SCOTOMA

- Monocular:
  - Central scotoma (AMD, CRAO, macula edema, CSR, DR).

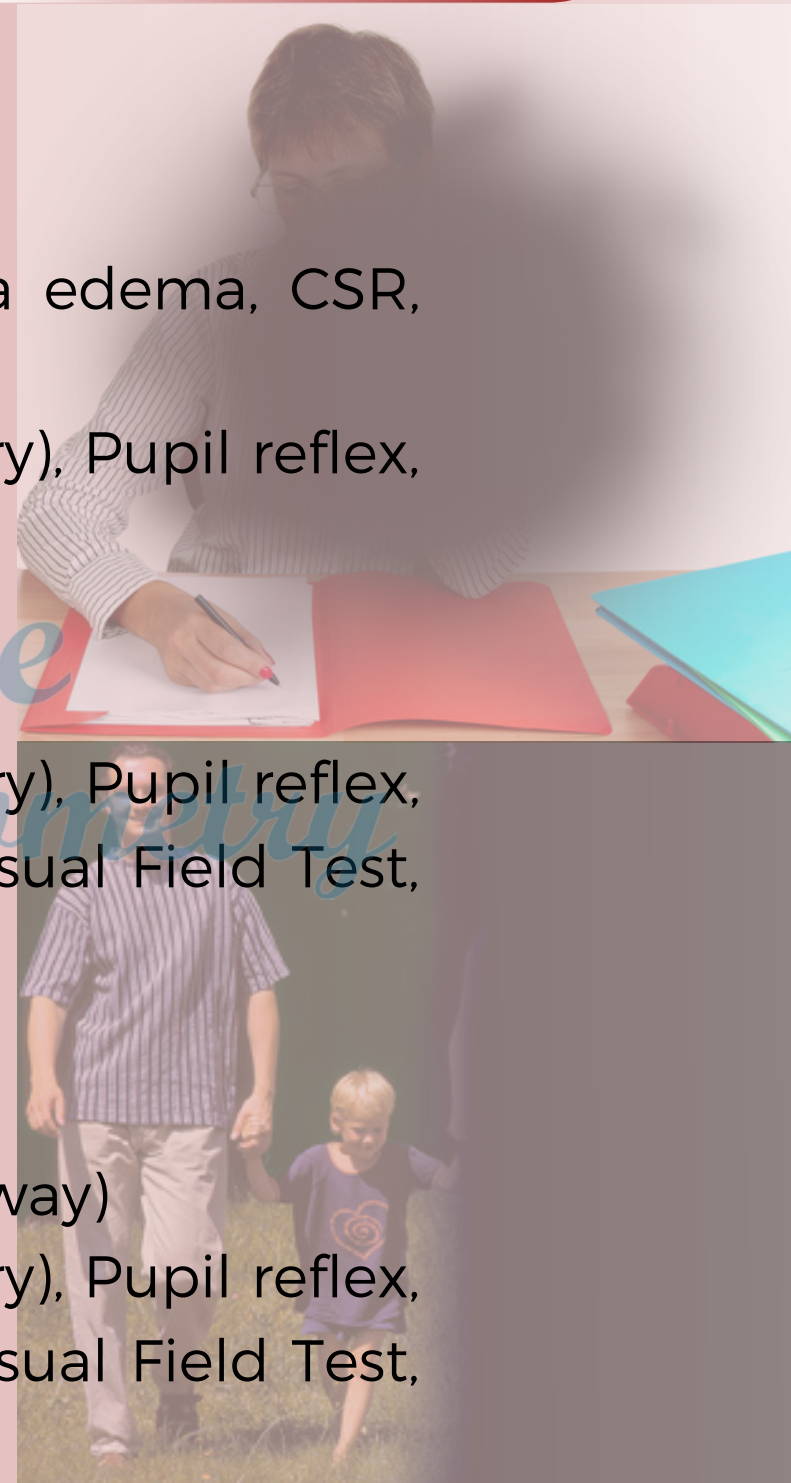
**Test to perform:** VA, Refraction (if necessary), Pupil reflex, slit lamp examination OCT, Funduscopy.

- Para Central scotoma (Glaucoma)

**Test to perform:** VA, Refraction (if necessary), Pupil reflex, slit lamp examination OCT, Funduscopy, Visual Field Test, Amsler Grid

- Binocular:
  - Hemianopia (lesion in optic nerve pathway)

**Test to perform:** VA, Refraction (if necessary), Pupil reflex, slit lamp examination OCT, Funduscopy, Visual Field Test, Amsler Grid.






Wow, what a cool content



Leave your comments



Share with friends



Save, to consult in the future

# The World of optometry



The World of Optometry

#TwopTips



@theworldofoptometry



TheWorldofOptometry



TheWorldofOptometry