

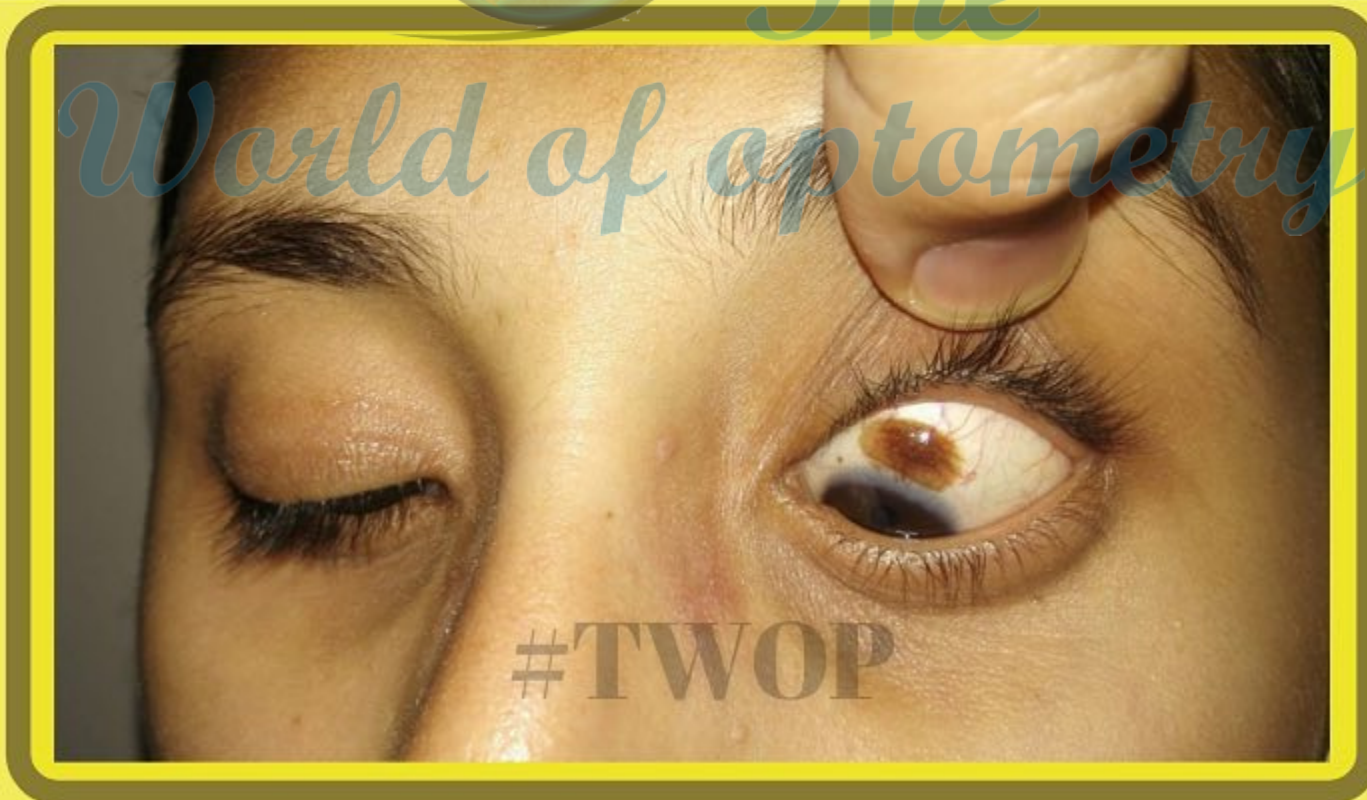TWOP Discussion

CONJUNCTIVAL MELANOSIS




The

World of optometry



#TWOP


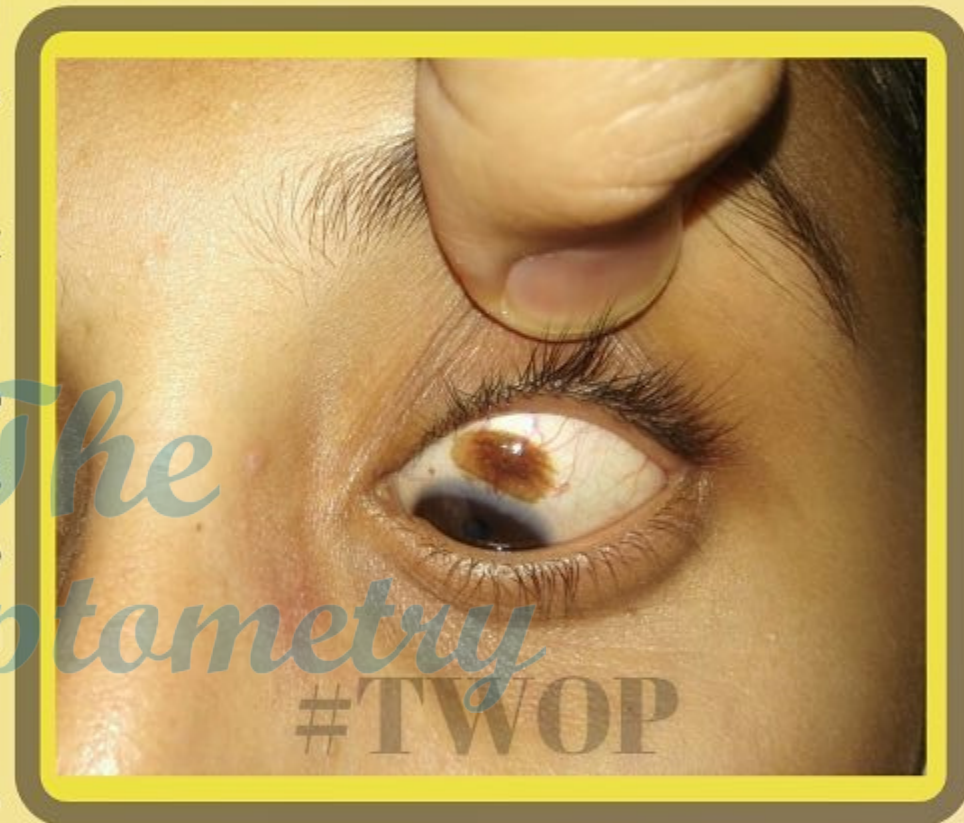


ANSWER

Conjunctival Melanosis:

Conjunctival primary acquired melanosis (PAM) is a non-cystic, painless, uneven, brownish pigmented lesion of the conjunctival epithelium. It can be found in any part of conjunctiva but usually in bulbar conjunctiva, due to the proliferation of atypical melanocytes in the epithelium that do not invade the subepithelial tissue. Typically occurs in one eye only.

Treatment includes excisional biopsy, alcohol epitheliectomy, cryotherapy, chemotherapy eye drops to avoid developing melanoma.



#TWOP Discussion



Wow, what cool content



Leave your comment



Share with friends



Save, to consult in the future

The World of optometry

